

Investigations on the morphology of the quail's ear (*Coturnix coturnix*)

med. vet. Anna Bonsmann

Clinic for Zoo Animals, Exotic Pets and Wildlife,
University of Zurich, Vetsuisse Faculty, Switzerland

Customer need

Although avian auricular anatomy has received attention by various authors, little importance is attached to the avian ear in veterinary practice. This could be due to the inaccessible location and limited knowledge on anatomy and diseases. The primary goal of the study was the creation of a 3D model of the quail's ear that should assist the observer in identifying structures and recognizing the spatial

relationships at this small, inaccessible location.

Approach

As histological sections of the quail's ear were already available, a first approach was the construction of a detail-rich 3D model from histological sections. Sections were aligned and laid above each other. Mainly three factors rendered this approach impossible: Misalignment occurred due to artefacts in histological sections, such as contusions and distortions due to the cutting process and manipulation of tissue specimens. Different intensities in dyeing led to difficulties in threshold segmentation. As only every tenth section was retained, limited resolution in the stack plane occurred.

Customer need

Revealing the morphology of the quail's ear and the creation of a 3D-model. Essential for segmentation is a high resolution of delicate bony structures, a perfectly aligned dataset and distinct grey-scale values that can be assigned to different materials.

Approach

Three imaging techniques (histology, high-field-MRI and micro-CT) have been utilized to depict the quail's ear morphology. After comparing imaging methods, it was decided to use micro-CT data for the creation of a 3D-model of the quail's left ear.

Materials and methods

SCANCO Medical μ CT 100 was used to produce the images.

Results

The created 3D-model can be handled in a 3D-PDF without further software necessary. For the creation of an anatomical atlas of the quail's ear, 17 histological sections were chosen, labelled and aligned to the reference model. A comparison of histological section, 2D-microCT and open ear model is given and magnifications of histological sections were labelled.

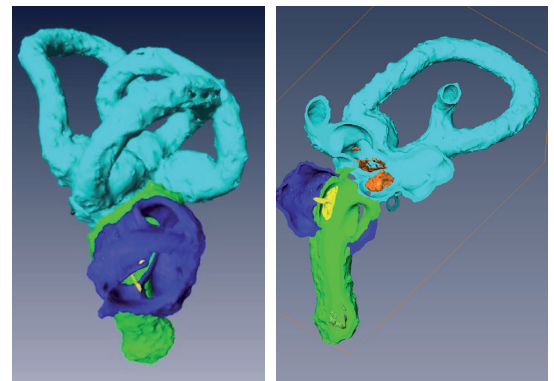


Figure 1: The model of the quail's left inner ear and columella. Green: Cochlea; yellow: Columella; Dark blue: combined Recessus columellae and Recessus scalae tympani; turquoise: vestibular apparatus with Utriculus, Sacculus and three semicircular ducts.

Left: Oblique lateral view on the 3D-model. A rough surface originates due to trabeculae that embed the osseous labyrinth in the skull and that have been cut.
Right: Longitudinal section through the cochlea of the 3D model, view on the inside. Note statoconia in the apical end of cochlea (Lagena; Statoconia green) and statoconia in sacculus and utriculus (orange).

So it was decided to use a micro-CT and a high field MRI to overcome these issues and reveal the quail's ear morphology. The advantages of these techniques comprise the avoidance of tissue destruction, the velocity compared to the creation of histological sections as well as the generation of perfectly aligned datasets that can be reformatted in any plane and contain isometric and size-calibrated voxels. Because of its non-destructiveness the same head-specimen was investigated with both techniques.

When comparing high-field MRI and micro-CT, we gained an inferior resolution of 80 $\mu\text{m}/\text{Voxel}$ in high-field-MRI that did not permit the detection of small soft tissue structures such as the tympanic membrane. Susceptibility-artefacts occurred in the MRI scan of the quail's head, as the head is very pneumatised.

In micro-CT scan, resolutions of 11.4 $\mu\text{m}/\text{Voxel}$ to 17.2 μm were reached. Bony structures were delineated with superior contrast and spatial resolution. On the other hand, soft tissue structures were difficult to delimit. As the inner ear is embedded in bone (bony labyrinth), this technique was chosen for the creation of a 3D-model.

Material and methods

All micro-CT data presented below were generated with the Scanco μCT 100 (SCANCO Medical AG, Brüttisellen, Switzerland).

The head of a quail is approximately 4.5 cm in length and 2.5 cm in height. Of primary importance was the creation of a high resolution dataset while scanning the whole head. As the scan was performed on a dead specimen and only two scans were processed further, scan duration and data storage played a minor part in our study.

Two scans were performed on a quail head specimen that was previously fixated in formalin. The scans were performed at a tube voltage of 70 kVp and a current of 114 μA .

First, the whole head was scanned. The isotropic voxel resolution was 17.2 μm in this scan. The scanning process lasted 19.1 hours and a 16 bit

DICOM-Image-Stack of 2108 pictures was obtained, covering a field of view of 35.23 mm and an image matrix of 2048x2048x2108 voxels. This scan was chosen for the creation of a 3D-model of the skull and the inner ear.

In a second scan, a smaller segment of the head (braincase) was chosen and an isotropic voxel size of 11.4 μm was achieved. The scanning process lasted 15.5 hours. In this scan, 1837 reconstructed cross-sections of 3072x3072 pixels were received. The isometric voxel size was 11.4 μm . This scan was used for measurements.

For the creation of the model and measurements, Amira 5.4 (FEI Visualization Sciences Group, FEI Corporate, Burlington, Massachusetts, USA) was used. A 3D-PDF was created following the supplementary 3D-PDF-protocol of de Boer et al. (2011) using Adobe Acrobat Pro Extended 9.1 and Adobe Illustrator CS4. For the creation of the anatomical atlas the 18 histological sections were chosen, digitalized using a slide scanner (Mirax Midi Slide Scanner, Carl Zeiss Microscopy GmbH, Jena, Germany) and aligned "manually" to the reference-CT-data and the 3D-model.

Results

Measurements of different diameters, lengths and ratios were performed and can serve as reference measures for the quail's auricular anatomy. The created 3D-model of the quail's ear can be seen in

Figure 1. It can be cut in any direction and handled freely.

The endocast of the inner ear is visualized in context to the skull in Figure 2. The inner ear occupies a large space in the cranium.

In the anatomical atlas, all pages are constructed in the following way: First the cutting planes of the histological section in the skull and in the ear are depicted, and a comparison of histological section, reference CT plane and open 3D-model is given (Figure 3). Labelled enlargements of the histological sections are then presented (Figure 4)

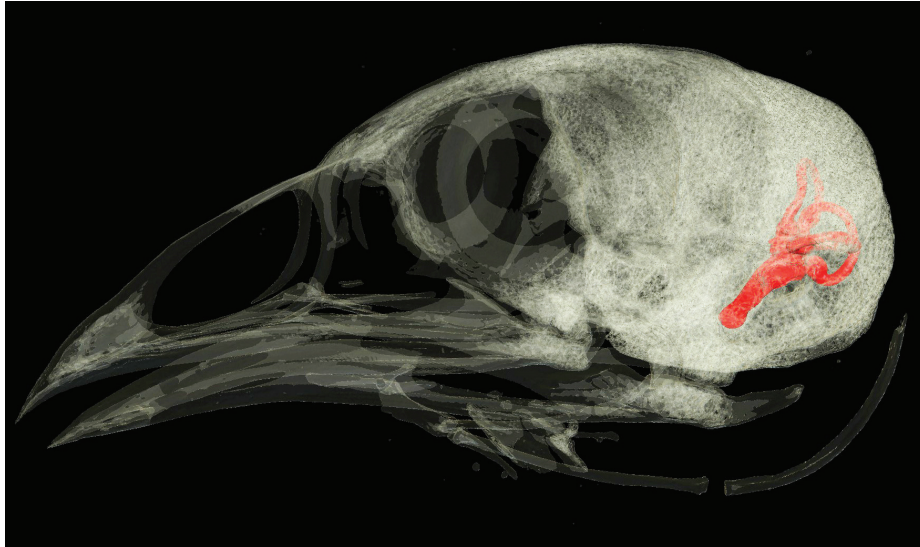


Figure 2: Left lateral view on the semitransparent skull: The inner ear endocast is rendered red, the position and size in the skull are revealed.

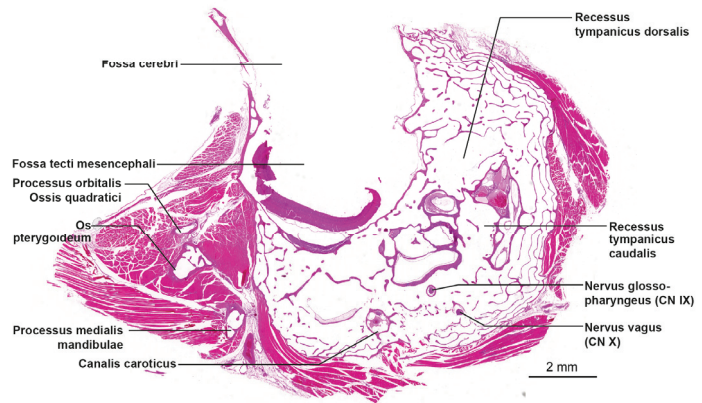
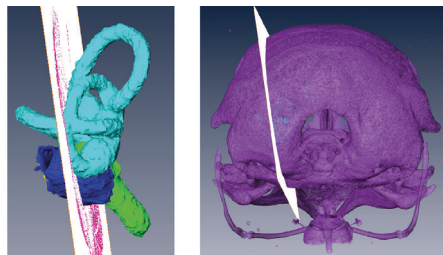
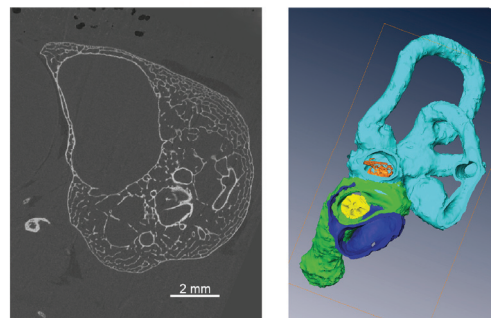


Figure 3: One exemplary overview-page from the anatomical atlas. On top the cutting plane of the histological section in the segmented skull and segmented ear are depicted. Below a comparison of histological section, reference CT plane and open 3D-model is given.



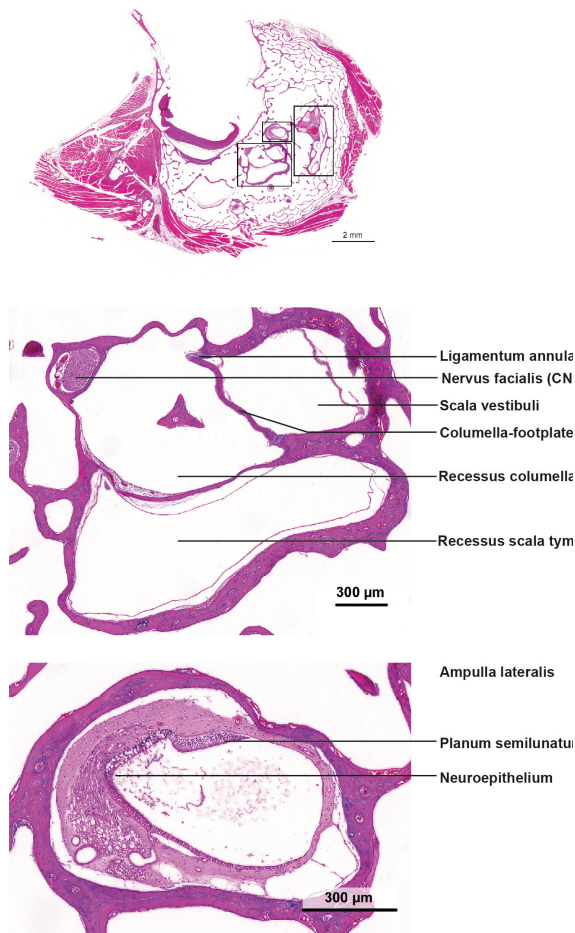


Figure 4 After the overview, labelled enlargements of the histological sections are presented on the following pages.

A comparison of the quail's ear with that of other birds and mammals can be found in the monograph.

Conclusion

Micro-CT data is suited for the creation of a 3D-model of the inner ear, as this structure is embedded in bone. Furthermore a high resolution and very good signal to noise ratio make a micro-CT scan an adequate method for the depiction of the quail's skull with all filigran osseous structures (eg. Columella (auditory ossicle) of the quail measures 1.66 mm in length).

It was impossible to evaluate soft tissue structures, such as the tympanic membrane or the secondary tympanic membrane. If a high soft tissue detail is necessary, an approach with x-ray contrast medium as described by Metscher (2009) or a combination of

micro-CT with another technique as presented by Buytaert et al. (2011) is a possibility.

References

Buytaert JAN, Salih WHM, Dierick M, Jacobs P, Dirckx JJJ (2011)

Realistic 3D computer model of the gerbil middle ear, featuring accurate morphology of bone and soft tissue structures.

Journal of the Association for Research in Otolaryngology 12:681-696

de Boer BA, Soufan AT, Hagoort J, Mohun TJ, van den Hoff MJB, Hasman A, Voorbraak FPJM, Moorman AFM, Ruijter JM (2011)

The interactive presentation of 3D information obtained from reconstructed datasets and 3D placement of single histological sections with the 3D portable document format.

Development 138:159-167

Metscher BD (2009)

MicroCT for comparative morphology: Simple staining methods allow high-contrast 3D imaging of diverse non-mineralized animal tissues.

BMC Physiology 9:11

SCANCO equipment

SCANCO Medical µCT 100 scanner

SCANCO software

Measurement program incl. ScoutView
Automatic reconstruction software
DICOM converter